

See discussions, stats, and author profiles for this publication at: <https://www.researchgate.net/publication/236958087>

Portomesenteric Thrombosis Following Laparoscopic Bariatric Surgery Incidence, Patterns of Clinical Presentation, and Etiology in a Bariatric Patient Population

Article in Archives of Surgery · April 2013

DOI: 10.1001/jamasurg.2013.1053 · Source: PubMed

CITATIONS

51

READS

126

7 authors, including:



David Goitein

Sheba Medical Center

116 PUBLICATIONS 1,860 CITATIONS

SEE PROFILE



Ibrahim Matter

Bnai Zion Medical Center, Haifa

78 PUBLICATIONS 1,984 CITATIONS

SEE PROFILE



Asnat Raziel

Assuta Medical Centers

89 PUBLICATIONS 876 CITATIONS

SEE PROFILE



David Hazzan

Carmel Medical Center

63 PUBLICATIONS 842 CITATIONS

SEE PROFILE

Some of the authors of this publication are also working on these related projects:



Roux-y Bypass Complications [View project](#)



Complications of bariatric surgery [View project](#)

ONLINE FIRST

Portomesenteric Thrombosis Following Laparoscopic Bariatric Surgery

Incidence, Patterns of Clinical Presentation, and Etiology in a Bariatric Patient Population

David Goitein, MD; Ibrahim Matter, MD; Asnat Raziel, MD; Andrei Keidar, MD; David Hazzan, MD; Uri Rimon, MD; Nasser Sakran, MD

Objective: To describe the incidence of, the patterns of clinical presentation of, and the reasons for portomesenteric vein thrombosis among patients who underwent laparoscopic bariatric surgery.

Design: Retrospective, multicenter study.

Setting: Six academic bariatric centers.

Patients: Morbidly obese patients diagnosed with portomesenteric vein thrombosis following laparoscopic bariatric surgery between January 2007 and June 2012.

Main Outcome Measures: Clinical presentation, diagnostic measures used, treatments employed, outcome, and hematologic workup of patients.

Results: Of 5706 patients who underwent laparoscopic bariatric surgery, 17 (0.3%) had portomesenteric vein thrombosis, 16 after sleeve gastrectomy and 1 following adjustable gastric banding. Seven patients were women, the mean age was 38 years, and the mean body mass index was 44.3. The median time to presentation was 10.1

days, and the median time to diagnosis was 11.7 days. New-onset epigastric pain was present in all patients, whereas other signs and symptoms were sporadically found. Computed tomography was performed and was diagnostic in 16 cases. Ultrasonography was used for 9 patients, and positive results were found for 8 of these patients. Patients were treated by anticoagulation with subcutaneous low-molecular-weight heparin (n=15) or intravenous heparin (n=2), followed by warfarin sodium. One patient underwent transhepatic portal infusion of streptokinase. Three patients required surgery: laparoscopic splenectomy due to infarct and abscess for 1 patient and laparotomy for 2 patients (with necrotic small-bowel resection for 1 of these patients). There were no deaths.

Conclusions: Portomesenteric vein thrombosis is rare after laparoscopic bariatric surgery. Familiarity with this dangerous entity is important. Prompt diagnosis and care, initiated by a high index of suspicion, is crucial.

Arch Surg. Published online December 17, 2012.
doi:10.1001/jamasurg.2013.1053

BARIATRIC SURGERY HAS BECOME the mainstay of treatment for morbid obesity with many thousands of procedures performed annually.¹ It has been shown to significantly help patients lose weight and improve obesity-related comorbidities, quality of life, and survival.^{2,3} Despite these positive results, all bariatric procedures have inherent complications that invariably affect a patient's disposition and well-being and that occur in 10% to 40% of cases.^{4,5}

Morbidly obese patients are considered at high risk for thromboembolic events, and most centers advocate a regimen of venous thrombotic event (VTE) prophylaxis, including anticoagulation ini-

tiated before surgery and continued postoperatively up to patient discharge or sometimes for 2 to 4 weeks after surgery.⁶⁻⁹ Early ambulation is uniformly encouraged.

Pulmonary embolism is 1 of the 2 major causes of postoperative mortality (the other being septic complications of a leak).⁵ Bleeding complications, although rarely lethal, are more common and, when present, sometimes mandate avoidance or cessation of anticoagulation during the perioperative period.⁹

Portomesenteric vein thrombosis (PMVT) is a rare but potentially lethal condition that has been described as occurring as a result of local or systemic etiologies. Postsurgical PMVT is most common after procedures including ligation of, ma-

Author Affiliations are listed at the end of this article.

nipulation of, or injury to the portomesenteric venous system, such as splenectomy, liver transplantation, and the use of portal-systemic shunts.¹⁰⁻¹³ Portomesenteric vein thrombosis has been implicated after laparoscopic surgery as well.¹⁴ Suggested causative factors include venous stasis from increased intra-abdominal pressure, intraoperative manipulation of splanchnic vasculature, and systemic hypercoagulable states. Portomesenteric vein thrombosis after laparoscopic bariatric surgery (LBS) has appeared in case reports since 2002, after laparoscopic Roux-en-Y gastric bypass (LRYGB), laparoscopic sleeve gastrectomy (LSG), and laparoscopic adjustable gastric banding.¹⁴⁻²⁴

The aim of our study was to determine the incidence of, the patterns of clinical presentation of, and the potential reasons for PSVT after bariatric surgery. We herein report on a multicenter series of 17 patients who had PMVT after LBS.

METHODS

Six bariatric centers in Israel participated in our study, each maintaining a prospectively collected database of all bariatric procedures performed. Local ethical committee approval for database management was obtained at each center. The retrospective analysis of these databases was performed by querying all the patients who underwent an LBS between January 2007 and June 2012. The data collected included demographics; anthropometric measurements; medical and surgical histories; type of procedure; operative and postoperative courses; length of hospital stay; times to symptom onset and diagnosis; clinical, laboratory, and imaging findings; treatment; and outcome.

Surgical technique varied slightly among centers, but all procedures were performed by experienced bariatric surgeons who were well beyond their learning curve. Statistical analysis of data was performed using SPSS version 11.0 (SPSS Inc). The distributions of continuous variables were assessed for normality using the Kolmogorov-Smirnov test (cut off at $P = .01$). Normally distributed continuous variables were described as mean (standard deviation) values, whereas continuous variables with distributions significantly deviating from normal were described as median (minimum-maximum) values. Continuous variables were compared by using the *t* test for independent samples. Categorical variables were described using frequency distributions and are presented as frequencies (ie, percentages). Categorical variables were compared using the χ^2 test or the Fisher exact test, as necessary. All tests are 2-tailed and considered statistically significant at $P < .05$.

RESULTS

Between January 2007 and June 2012, a total of 5706 patients underwent LBS by experienced bariatric surgeons at 6 academic bariatric centers. The most common procedure performed was LSG (4355 patients [76.3%]), followed by LRYGB (966 patients [16.9%]), laparoscopic adjustable gastric banding (243 patients [4.3%]), and biliopancreatic diversion (142 patients [2.5%]). The mean age was 45 years, the mean body mass index (calculated as weight in kilograms divided by height in meters squared) was 44.4, and the mean hospital length of stay was 2.8 days. Major complications occurred in 5.4% of all patients who underwent LBS. The mortality rate was

0.12%. Perioperative VTE prophylaxis was administered at all centers and included pneumatic compression stockings placed before induction of anesthesia and subcutaneous enoxaparin sodium administered once daily, but it varied slightly with regard to length of treatment (2 centers continued enoxaparin after the patients were discharged).

Of 5706 patients who underwent LBS, 17 (0.3%; PMVT frequency range of the 6 different centers, 0.1%-0.4%) developed clinically apparent PMVT. Of these 17 patients, 7 (41.2%) were women. The mean (SD) age was 38 (9.9) years, the mean (SD) body mass index was 44.3 (3.9), and the mean hospital length of stay was 2 (0.5) days. Four of the 17 patients had a previous history of deep vein thrombosis, and 2 of pulmonary embolism (1 patient had both), for an overall rate of VTEs of 29%. This contrasts markedly with the rate of VTEs in patients who did not develop this complication, which was 3% ($P < .001$; relative risk, 9.80 [95% CI, 0.02-0.03]). None of the patients had a known coagulopathy. Two of the 7 women took oral contraceptives, and they did not stop taking them prior to surgery.

Patients began experiencing symptoms after a median (SD) of 10.1 (3.7) days (range, 3-42 days) after surgery, all but 2 after they were discharged from the hospital. Diagnosis of PMVT was made a median of 2 days (range, 0-13 days) after symptom onset. The most prevalent symptom was a new-onset, nonspecific epigastric pain, which was present in all patients. The pain sometimes radiated to the back or left scapular region (5 patients [29.4%]). Ten patients (58.8%) had experienced associated nausea and/or vomiting. Fever was recorded for 5 patients, and hematemesis for 1.

Plane abdominal radiographic images were obtained for all patients but were uniformly nondiagnostic. Computed tomography (CT) was used next and was diagnostic for all patients (**Figure 1**). Thrombi were identified in the portal vein (13 patients) and its branches (4 patients), the superior mesenteric vein (7 patients), and the splenic vein (6 patients) in various combinations thereof.

Doppler ultrasonography was performed to confirm the diagnosis and to enable a follow-up that was not dependent on ionizing radiographic imaging for 10 of the 17 patients. For all but 1 of the 10 patients, the results were informative and confirmed the CT findings. One study was inconclusive owing to technical difficulties. Enoxaparin was administered subcutaneously to 15 patients at a dosage of 1.5 to 2 mg/kg, divided into 2 daily administrations (80-100 mg twice a day) immediately following diagnosis. Intravenous heparin was administered to 2 patients, and a partial thromboplastin time of 60 to 90 seconds was achieved. This regimen was continued for 4 to 7 days. Warfarin treatment was concomitantly initiated until therapeutic levels were achieved (international normalized ratio, 2.5-3) for all patients. The choice of anticoagulation was based on the hematologic consultations at each center.

Three of the patients had a more fulminant course. They were readmitted to the hospital (3 different centers) after a seemingly normal postoperative recovery following LSG, and all of them were discharged on postoperative day 3. Diagnosis was established with CT on

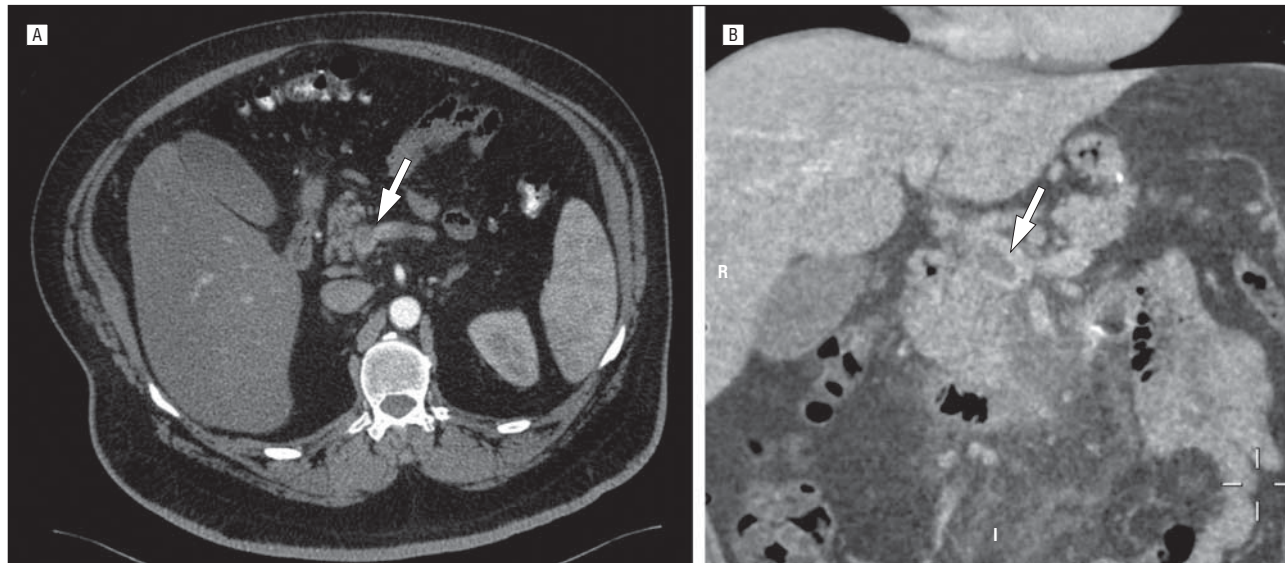


Figure 1. Contrast-enhanced, computed tomographic images (axial image [A] and coronal reconstruction [B]) depicting a thrombus in the portal vein (arrowheads).

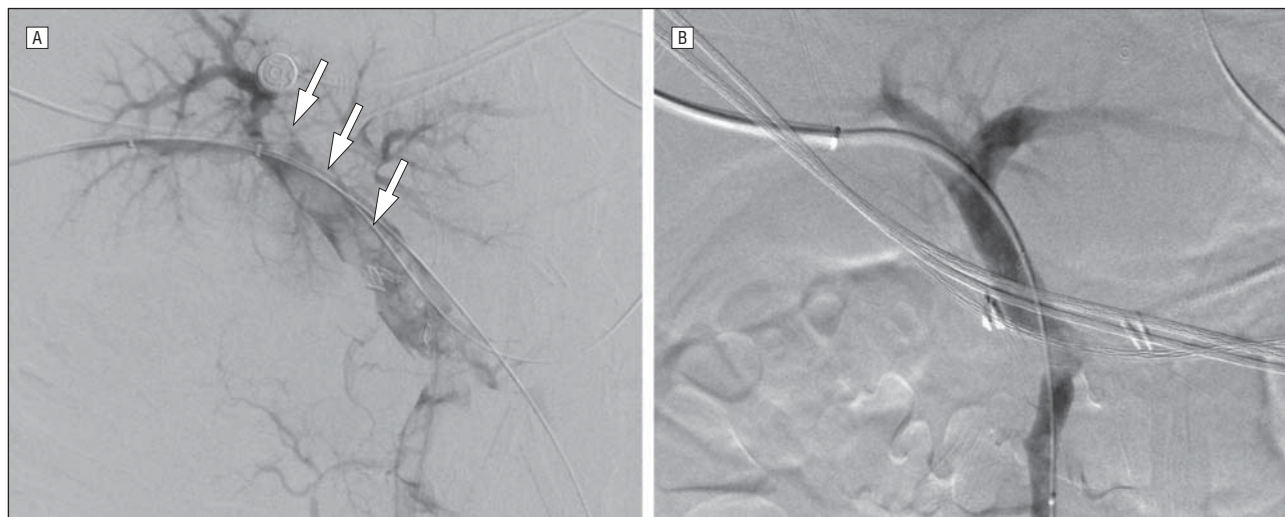


Figure 2. Percutaneous, transhepatic portal venographic images. A, The filling defects (arrowheads) along the portal vein indicate a near-occluding thrombus. B, This image was obtained after instillation of urokinase for 2 days via an indwelling catheter, and the renewal of unhindered portal flow is apparent.

admission for 2 patients and 3 days later for the third patient.

The first patient was found to have complete portal vein thrombosis with ascitic fluid and a segment of the jejunum that was edematous. He developed severe abdominal pain with peritoneal irritation and underwent exploratory laparotomy. An edematous, ischemic (but viable) segment of the jejunum with sanguineous ascitic fluid was found. No resection was performed, the abdomen was closed using a “Bogota bag,” and the patient was taken for an angiography. Percutaneous, transhepatic catheterization of the portal vein was performed, thrombosis was verified, and urokinase was instilled. Continuous infusion succeeded in reestablishing portal flow after 2 days (**Figure 2**). The patient underwent a “second look” laparotomy, he was found to have a viable small bowel, and a third operation for verification and abdominal closure was performed.

The second patient returned to the emergency department 21 days after surgery complaining of severe new-onset epigastric pain, nausea, and vomiting. He was tachycardic and had a tender, slightly distended abdomen; leukocytosis; and acidosis. A CT scan revealed portal vein thrombosis, ascitic fluid, and an ischemic small bowel with intramural gas (pneumatosis intestinalis); he underwent an exploratory laparotomy. Two meters of necrotic jejunum were resected with primary anastomosis. Intravenous heparin was initiated and later switched to warfarin with a target international normalized ratio of 3. The patient recovered slowly without further sequelae.

The third patient became septic 3 days after admission and was found to have a splenic vein thrombosis with splenic infarct and abscess formation. She underwent a laparoscopic splenectomy and slowly recovered with no further complications.

Table 1. Possible Etiologies for Portomesenteric Vein Thrombosis

| Etiology | Condition |
|---|--|
| Systemic | |
| Hereditary thrombophilia | Protein S, protein C, antithrombin 3, and factor V Leiden deficiencies; homocysteinemia |
| Acquired prothrombotic states | Abdominal sepsis; pregnancy; contraceptive use; malignancy; myeloproliferative disease; obesity |
| Local | |
| Trauma to portal venous system | |
| Abdominal inflammation | Pancreatitis; appendicitis; diverticulitis |
| Abdominal malignant neoplasm | |
| Decreased portal flow | Ascites; cirrhosis; portal hypertension |
| "Surgical" | |
| Direct trauma to portomesenteric system | |
| Diminished blood flow | Transient decreased venous return (eg, reverse Trendelenburg position and increased intra-abdominal pressure); tributary ligation (eg, splenic vein and short gastrics); postoperative dehydration |

For all 17 patients, resolution of the presenting symptoms was the rule, and all are doing well with sufficient and comparable weight loss during a mean follow-up of 18 months (range, 4-64 months). All 17 patients were treated with warfarin for a period of 6 to 12 months after hospital discharge, as recommended by a hematologist. Routine follow-up imaging was not performed for any of these patients; however, 2 patients who required abdominal imaging for unrelated causes were incidentally found to have a cavernous transformation of the portal vein.

All 17 patients underwent a formal hematological workup for evaluation of hypercoagulability after hospital discharge. Three patients (17.6%) were abnormal, with 2 having factor V Leiden deficiency and 1 having protein S, protein C, and methylenetetrahydrofolate reductase deficiencies.

COMMENT

Portomesenteric vein thrombosis is a rare phenomenon. In the English literature, portal vein obstruction was first reported in 1868 by Balfour and Stewart,²⁵ who described a patient presenting with an enlarged spleen, ascites, and variceal dilatation. Possible etiologies may be systemic (such as inherited hypercoagulable or acquired prothrombotic states) or local (such as intra-abdominal inflammatory or neoplastic disease, diminished flow in cirrhosis, or portal hypertension) (**Table 1**).

Portal vein thrombosis was described as a postsurgical complication following splenectomy in 1895 by Delatour²⁶ and has since been described following several other procedures. The postsurgical PMVT may be attributed

to direct trauma to the portomesenteric structures, diminished flow due to ligation of tributary vessels, and the local inflammatory response to surgery. Laparoscopy entails a thrombogenic effect due to increased intra-abdominal pressure with reduction in venous return from the extremities (especially in the steep reverse Trendelenburg position used in LBS) and splanchnic system.²⁷⁻²⁹ Portomesenteric vein thrombosis has been reported after laparoscopic procedures including splenectomy, colectomy, appendectomy, fundoplication, cholecystectomy, and bariatric surgery.^{10,14,16-18,20,21,24,30}

Obesity is considered a hypercoagulable state with a higher-than-average risk for thromboembolic events. This is attributed to several factors, including the chronic inflammatory state associated with obesity, increased abdominal pressure, lower-extremity venous stasis, and a sedentary lifestyle.^{7,8,31}

A history of VTEs was present in almost a third of the patients who subsequently developed PMVT. There was a highly significant difference in this proportion when compared with the patients who did not succumb to this complication (29% vs 3%; $P < .001$; relative risk, 9.8), making a history of VTEs an important risk factor for PMVT formation.

Venous thrombotic event prophylaxis is used by most bariatric centers, and many different regimens are used with regard to the time of initiation, the specific pharmacologic agent used, the dosage, the length of treatment, and the adjunct appliances used (eg, pneumatic compression stockings and inferior vena cava filters).^{6-9,32,33}

Venous thrombotic event prophylaxis was used in all the centers that participated in our study, but it did not prevent PMVT. We cannot comment on its efficacy in this regard because the present study is a retrospective observational study.

Postbariatric surgery-related PMVT has been described in several case reports and 3 series^{14,16-22,24} (**Table 2**) and usually manifests as nonspecific abdominal pain. However, the clinical presentation varies widely, and the diagnosis may be delayed. Patients may experience nausea, vomiting, diarrhea, or gastrointestinal tract bleeding. Most patients have had symptoms for more than 2 days before seeking medical care. Physical findings vary and range from no physical findings to low-grade fever, mild abdominal tenderness, peritoneal signs, or frank shock due to bowel ischemia. It may be speculated that, after bariatric surgery, some of the patients who experience vague epigastric pain with some degree of dehydration might, in fact, have a mild, more chronic form of PMVT that is never diagnosed and spontaneously resolves. The cases that reach medical attention and are severe enough to warrant a radiologic workup are the ones diagnosed with this entity. Therefore, the true incidence of PMVT may be underestimated, in a way similar to that of pulmonary embolism.³⁴

In our patient group, the diagnosis of PMVT was not difficult to obtain. Patients presenting to the emergency department with severe, though nonspecific, abdominal pain after bariatric surgery undergo contrast-enhanced abdominal CT imaging, as part of the initial workup, to look for the more common complications (such as leaks and fluid collections). Portomesenteric vein

Table 2. English Language Publications of Portomesenteric Thrombosis Following Bariatric Surgery

| Source | Procedure(s) | Patients, ^a No. | | | | Results of Hematologic Workup |
|--|--------------|----------------------------|-----|------|-----|---|
| | | Total | PVT | SMVT | SVT | |
| Bellanger et al, ¹⁵ 2010 | LSG | 3 | 2 | 2 | 2 | Negative for all 3 patients |
| Berthet et al, ¹⁶ 2009 | LSG | 1 | 1 | 1 | 1 | Factor II Leiden deficiency |
| Calmes et al, ¹⁷ 2002 | LAGB | 1 | 1 | 0 | 1 | Negative |
| Denne and Kowalski, ¹⁸ 2005 | LRYGB | 1 | 1 | 0 | 0 | Not reported |
| Gandhi et al, ¹⁹ 2010 | LRYGB | 1 | 0 | 1 | 0 | Negative |
| James et al, ¹⁴ 2009 | LRYGB | 7 | 4 | 6 | 1 | Not reported for all 7 patients |
| Pigeyre et al, ²¹ 2008 | LRYGB | 1 | 1 | 1 | 1 | Protein S deficiency |
| Singh et al, ²² 2010 | LSG | 1 | 0 | 1 | 0 | Negative |
| Sonpal et al, ²³ 2004 | RYGB | 1 | 0 | 1 | 0 | Negative |
| Swartz and Felix, ²⁴ 2004 | LRYGB | 3 | 0 | 3 | 0 | Not reported for 2 patients; negative for 1 patient |
| Total | | 20 | 10 | 16 | 5 | |

Abbreviations: LAGB, laparoscopic adjustable gastric banding; LRYGB, laparoscopic Roux-en-Y gastric bypass; LSG, laparoscopic sleeve gastrectomy; PVT, portal vein thrombosis; RYGB, Roux-en-Y gastric bypass; SMVT, superior mesenteric vein thrombosis; SVT, splenic vein thrombosis.

^aSome patients had more than 1 type of thrombosis.

Table 3. Treatment Options for Portomesenteric Vein Thrombosis

| Treatment Option | Details |
|---------------------------------|--|
| Rehydration and supportive care | |
| Anticoagulation | Low-molecular-weight heparin ^a ; intravenous heparin ^b |
| Thrombolysis | Percutaneous-transhepatic portal vein catheterization |
| Laparoscopy/laparotomy | Resect necrotic bowel; relieve abdominal pressure; possible direct thrombolysis/thrombectomy |

^aDosage of 0.5 to 1 mg/kg twice a day.

^bPartial thromboplastin time of 60 to 90 seconds.

thrombosis is readily diagnosed using this modality, as was the case for all the patients in our cohort.

Our patients began experiencing new-onset epigastric pain, usually after being discharged from the hospital. This leads us to speculate that perhaps the relative difficulty these patients have with fluid intake (a propensity for mild dehydration, together with the aforementioned risk factors for thrombosis) puts them at a greater risk for this rare complication.

Fourteen of the 17 patients (82.4%) had an indolent course that did not mandate any intervention other than careful observation, hydration, anticoagulation, and analgesia. However, 3 patients had a fulminant course necessitating surgical and other invasive interventions. Fortunately, there were no deaths in our cohort.

Treatment options vary according to the severity of the disease and its sequelae. Initial supportive measures include rehydration and bowel rest. Full anticoagulation with either subcutaneous low-molecular-weight heparin (1.5-2 mg/kg, divided into 2 daily administrations) or intravenous unfractionated heparin (titered to a partial thromboplastin time of 60-90 seconds) is given to patients who do not develop bowel ischemia or necrosis. This treatment is continued and changed to oral anticoagulants (target international normalized ratio, 2.5-3) that

should be continued for several months (the length of which will depend on coagulation profiles and a formal hematologic consultation).^{35,36} For patients with a more severe presentation and with symptoms and/or imaging findings compatible with a ischemic bowel, percutaneous, transhepatic thrombolytic therapy may be attempted (requiring a technical setup and a technical expertise that are not available in all institutions).^{37,38} For example, patients with peritonitis, sepsis, or perforation require an immediate exploration and resection of the necrotic bowel, if identified. A direct portomesenteric thrombectomy or thrombolysis is also possible in select cases^{39,40} (**Table 3**).

We propose 3 possible mechanisms by which LBS might instigate PMVT, in addition to the rare, sporadic cases encountered in general laparoscopic surgery:

1. The change in blood flow (namely, venous return from the stomach) occurs after LSG because of the division of the short gastric vessels. The altered flow may be a factor in PMVT promotion, similar to the state after fundoplication, which has been implicated before in this regard.^{14,41,42} It is interesting to note that, in this large cohort of patients who underwent LBS, all cases of PMVT but one occurred after LSG (the most common procedure in this group), with none after LRYGB or biliopancreatic diversion. Although biliopancreatic diversion was infrequently used, LRYGB contributed almost 1000 cases in which PMVT was not encountered. This difference in proportions was not statistically significant.

2. In patients who undergo LSG or LRYGB, direct physical contact with the splenic vein is possible while the surgeon is working in the lesser omental bursa. Intimal damage may inadvertently occur and cause later thrombosis.

3. After bariatric surgery, patients are usually discharged from the hospital soon after the procedure (in our series, the median length of stay was 2 days). Some patients encounter difficulty in reaching the suggested 2-L/d fluid intake and experience various degrees of dehydration. This may put them at a higher risk for thrombotic complications, deep vein thrombosis, pulmonary embolism, and PMVT.⁶⁻⁹

Our study has some limitations. First, it is a retrospective, nonrandomized study that was not designed to compare the 2 patient groups discussed. Being a multicenter study, there is an inconsistency regarding both surgical technique and VTE prophylaxis regimens. Because there was not a specific diagnostic or therapeutic protocol, there is variability in the modalities and interventions used, and no clear algorithm can be elucidated.

Despite these limitations, to the best of our knowledge, this is the first and largest series addressing the incidence, presentation, etiologies, treatment modalities, and outcomes of this rare but potentially lethal complication in bariatric surgery.

Portomesenteric vein thrombosis is an infrequent complication of LBS. Its true incidence is not known and is probably underestimated, but in this series of 5706 patients, it was diagnosed in 17 patients (0.3%). A previous history of VTEs is an important risk factor for PMVT formation, and its presence should prompt clinicians to consider an uncompromising prophylactic regimen for the patient. Familiarity with this entity, and a high index of suspicion, will allow for a prompt diagnosis and treatment. This would, hopefully, enable a swift and favorable resolution.

Accepted for Publication: August 30, 2012.

Published Online: December 17, 2012. doi:10.1001/jamasurg.2013.1053

Author Affiliations: Departments of Surgery C and Medical Imaging, Chaim Sheba Medical Center, Tel Hashomer (Drs Goitein and Rimon); Sackler School of Medicine, Tel Aviv University (Drs Goitein, Keidar, and Rimon), and Assia Medical, Assuta Hospital (Dr Raziell), Tel Aviv; Department of Surgery, Bnai Zion Medical Center (Dr Matter), and Ruth and Bruce Rappaport Faculty of Medicine, Technion Israel Institute of Technology (Drs Matter, Hazzan, and Sakran), and Department of Surgery B, Carmel Medical Center (Dr Hazzan), Haifa; Department of Surgery B, Rabin Medical Center, Petah Tikva (Dr Keidar); and Department of Surgery A, Hillel Yaffe Medical Center, Hadera (Dr Sakran), Israel.

Correspondence: David Goitein, MD, Department of Surgery C, Chaim Sheba Medical Center, Tel Hashomer, 52621 Israel (david.goitein@sheba.health.gov.il).

Author Contributions: *Study concept and design:* Goitein and Raziell. *Acquisition of data:* Goitein, Matter, Raziell, Keidar, Hazzan, Rimon, and Sakran. *Analysis and interpretation of data:* Goitein, Raziell, and Keidar. *Drafting of the manuscript:* Goitein, Raziell, and Rimon. *Critical revision of the manuscript for important intellectual content:* Matter, Raziell, Keidar, Hazzan, and Sakran. *Statistical analysis:* Raziell. *Administrative, technical, and material support:* Raziell and Rimon. *Study supervision:* Goitein, Matter, and Hazzan.

Conflict of Interest Disclosures: None reported.

REFERENCES

- Buchwald H, Oien DM. Metabolic/bariatric surgery Worldwide 2008. *Obes Surg.* 2009;19(12):1605-1611.
- Adams TD, Gress RE, Smith SC, et al. Long-term mortality after gastric bypass surgery. *N Engl J Med.* 2007;357(8):753-761.
- Buchwald H, Estok R, Fahrbach K, et al. Weight and type 2 diabetes after bariatric surgery: systematic review and meta-analysis. *Am J Med.* 2009;122(3):248.e5-256.e5.
- Encinosa WE, Bernard DM, Du D, Steiner CA. Recent improvements in bariatric surgery outcomes. *Med Care.* 2009;47(5):531-535.
- Flum DR, Belle SH, King WC, et al: Longitudinal Assessment of Bariatric Surgery (LABS) Consortium. Perioperative safety in the longitudinal assessment of bariatric surgery. *N Engl J Med.* 2009;361(5):445-454.
- Barba CA, Harrington C, Loewen M. Status of venous thromboembolism prophylaxis among bariatric surgeons: have we changed our practice during the past decade? *Surg Obes Relat Dis.* 2009;5(3):352-356.
- Hamad GG, Choban PS. Enoxaparin for thromboprophylaxis in morbidly obese patients undergoing bariatric surgery: findings of the prophylaxis against VTE outcomes in bariatric surgery patients receiving enoxaparin (PROBE) study. *Obes Surg.* 2005;15(10):1368-1374.
- Rocha AT, de Vasconcellos AG, da Luz Neto ER, Araújo DM, Alves ES, Lopes AA. Risk of venous thromboembolism and efficacy of thromboprophylaxis in hospitalized obese medical patients and in obese patients undergoing bariatric surgery. *Obes Surg.* 2006;16(12):1645-1655.
- Becattini C, Agnelli G, Manina G, Noya G, Rondelli F. Venous thromboembolism after laparoscopic bariatric surgery for morbid obesity: clinical burden and prevention. *Surg Obes Relat Dis.* 2012;8(1):108-115.
- Fichera A, Cicchiello LA, Mendelson DS, Greenstein AJ, Heimann TM. Superior mesenteric vein thrombosis after colectomy for inflammatory bowel disease: a not uncommon cause of postoperative acute abdominal pain. *Dis Colon Rectum.* 2003;46(5):643-648.
- Rattner DW, Ellman L, Warshaw AL. Portal vein thrombosis after elective splenectomy: an underappreciated, potentially lethal syndrome. *Arch Surg.* 1993;128(5):565-569; discussion 569-570.
- Sanabria JR, Hiruki T, Szalay DA, Tandan V, Gallinger S. Superior mesenteric vein thrombosis after the Whipple procedure: an aggressive, combined treatment approach. *Can J Surg.* 1997;40(6):467-470.
- Stieber AC, Zetti G, Todo S, et al. The spectrum of portal vein thrombosis in liver transplantation. *Ann Surg.* 1991;213(3):199-206.
- James AW, Rabl C, Westphalen AC, Fogarty PF, Posselt AM, Campos GM. Portomesenteric venous thrombosis after laparoscopic surgery: a systematic literature review. *Arch Surg.* 2009;144(6):520-526.
- Bellanger DE, Hargroder AG, Greenway FL. Mesenteric venous thrombosis after laparoscopic sleeve gastrectomy. *Surg Obes Relat Dis.* 2010;6(1):109-111.
- Berthet B, Bollon E, Valero R, Ouassini M, Sielezneff I, Sastre B. Portal vein thrombosis due to factor 2 Leiden in the post-operative course of a laparoscopic sleeve gastrectomy for morbid obesity. *Obes Surg.* 2009;19(10):1464-1467.
- Calmes JM, Bettschart V, Raffoul W, Suter M. Band infection with splenoportal venous thrombosis: an unusual but severe complication of gastric banding. *Obes Surg.* 2002;12(5):699-702.
- Denne JL, Kowalski C. Portal vein thrombosis after laparoscopic gastric bypass. *Obes Surg.* 2005;15(6):886-889.
- Gandhi K, Singh P, Sharma M, Desai H, Nelson J, Kaul A. Mesenteric vein thrombosis after laparoscopic gastric sleeve procedure. *J Thromb Thrombolysis.* 2010;30(2):179-183.
- Johnson CM, de la Torre RA, Scott JS, Johansen T. Mesenteric venous thrombosis after laparoscopic Roux-en-Y gastric bypass. *Surg Obes Relat Dis.* 2005;1(6):580-582; discussion 582-583.
- Pigeyre M, Seguy D, Arnalsteen L, Pattou F, Romon M. Laparoscopic gastric bypass complicated by portal venous thrombosis and severe neurological complications. *Obes Surg.* 2008;18(9):1203-1207.
- Singh P, Sharma M, Gandhi K, Nelson J, Kaul A. Acute mesenteric vein thrombosis after laparoscopic gastric sleeve surgery for morbid obesity. *Surg Obes Relat Dis.* 2010;6(1):107-108.
- Sonpal IM, Patterson L, Schreiber H, Benmeir A. Mesenteric venous thrombosis after gastric bypass. *Obes Surg.* 2004;14(3):419-421.
- Swartz DE, Felix EL. Acute mesenteric venous thrombosis following laparoscopic Roux-en-Y gastric bypass. *JLS.* 2004;8(2):165-169.
- Balfour GW, Stewart TG. Case of enlarged spleen complicated with ascites, both depending upon varicose dilatation and thrombosis of the portal vein. *Edinburgh Med J.* 1869;14:589-598.
- Delatour HB. III: thrombosis of the mesenteric veins as a cause of death after splenectomy. *Ann Surg.* 1895;21(1):24-28.
- Diebel LN, Dulchavsky SA, Wilson RF. Effect of increased intra-abdominal pressure on mesenteric arterial and intestinal mucosal blood flow. *J Trauma.* 1992;33(1):45-48; discussion 48-49.
- Diebel LN, Wilson RF, Dulchavsky SA, Saxe J. Effect of increased intra-abdominal pressure on hepatic arterial, portal venous, and hepatic microcirculatory blood flow. *J Trauma.* 1992;33(2):279-282; discussion 282-273.
- Goitein D, Pappasavas P, Yeane W, et al. Microsphere intestinal blood flow analy-

- sis during pneumoperitoneum using carbon dioxide and helium. *Surg Endosc*. 2005;19(4):541-545.
30. Maalouf M, Papasavas P, Goitein D, Caushaj PF, Gagne D. Portal vein thrombosis after laparoscopic splenectomy for systemic mastocytosis: a case report and review of the literature. *Surg Laparosc Endosc Percutan Tech*. 2008;18(2):219-221.
 31. Herron DM. C-reactive protein and adiposity: obesity as a systemic inflammatory state. *Surg Obes Relat Dis*. 2005;1(3):385-386.
 32. Mechanick JL, Kushner RF, Sugerman HJ, et al. American Association of Clinical Endocrinologists, The Obesity Society, and American Society for Metabolic & Bariatric Surgery Medical Guidelines for Clinical Practice for the perioperative nutritional, metabolic, and nonsurgical support of the bariatric surgery patient [published correction appears in *Surg Obes Relat Dis*. 2010;6(1):112]. *Surg Obes Relat Dis*. 2008;4(5)(suppl):S109-S184.
 33. Clinical Issues Committee of the American Society for Metabolic and Bariatric Surgery. Prophylactic measures to reduce the risk of venous thromboembolism in bariatric surgery patients. *Surg Obes Relat Dis*. 2007;3(5):494-495.
 34. Morpurgo M, Schmid C. The spectrum of pulmonary embolism: clinicopathologic correlations. *Chest*. 1995;107(1)(suppl):18S-20S.
 35. Condat B, Pessione F, Helene Denninger M, Hillaire S, Valla D. Recent portal or mesenteric venous thrombosis: increased recognition and frequent recanalization on anticoagulant therapy. *Hepatology*. 2000;32(3):466-470.
 36. Condat B, Pessione F, Hillaire S, et al. Current outcome of portal vein thrombosis in adults: risk and benefit of anticoagulant therapy. *Gastroenterology*. 2001;120(2):490-497.
 37. Kercher KW, Sing RF, Watson KW, Matthews BD, LeQuire MH, Heniford BT. Transhepatic thrombolysis in acute portal vein thrombosis after laparoscopic splenectomy. *Surg Laparosc Endosc Percutan Tech*. 2002;12(2):131-136.
 38. Ozkan U, Oğuzkurt L, Tercan F, Tokmak N. Percutaneous transhepatic thrombolysis in the treatment of acute portal venous thrombosis. *Diagn Interv Radiol*. 2006;12(2):105-107.
 39. Kaplan JL, Weintraub SL, Hunt JP, Gonzalez A, Lopera J, Brazzini A. Treatment of superior mesenteric and portal vein thrombosis with direct thrombolytic infusion via an operatively placed mesenteric catheter. *Am Surg*. 2004;70(7):600-604.
 40. Demertzis S, Ringe B, Gulba D, Rosenthal H, Pichlmayr R. Treatment of portal vein thrombosis by thrombectomy and regional thrombolysis. *Surgery*. 1994;115(3):389-393.
 41. García Díaz RA, Rodríguez-Sanjuán JC, Domínguez Díez RA, et al. Fatal portal thrombosis after laparoscopic Nissen fundoplication. *Rev Esp Enferm Dig*. 2005;97(9):666-669.
 42. Kempainen E, Kokkola A, Sirén J, Kiviluoto T. Superior mesenteric and portal vein thrombosis following laparoscopic Nissen fundoplication. *Dig Surg*. 2000;17(3):279-281.